

# Poster Presentation Report

SAFETY OF  
MATERNAL TESTOSTERONE  
THERAPY DURING

## BREAST FEEDING

**Rebecca L. Glaser, MD, FACS**

*Wright State University School of Medicine  
Millennium Wellness LLC  
Dayton, Ohio*

**Mark Newman, MS**

*ZRT Laboratory  
Beaverton, Oregon*

**Melanie Parsons, MASc**

*Millennium Wellness Australia  
Sydney, Australia*

**David Zava, PhD**

*ZRT Laboratory  
Beaverton, Oregon*

**Daniel Glaser-Garbrick**

*Centerville High School  
Dayton, Ohio*



**ABSTRACT** This article is an adaptation of an abstract/poster presentation made at the 13th International Congress on Steroidal Hormones and Hormones & Cancer, Quebec City, Canada (September 2008), concerning the topic of breast feeding as a contraindication to testosterone therapy. The purpose of the presentation and this article is to provide a summary of the findings of a study that was conducted to evaluate maternal absorption of testosterone and its excretion into breast milk by using three methods of delivery: sublingual drops, vaginal cream, and pellet implant. Testosterone was measurable in maternal blood by all three methods of delivery. No significant increase of testosterone was seen in breast milk when testosterone was delivered by vaginal cream, sublingual drops, or subcutaneous pellet implant. Testosterone was very low in infant blood at baseline and during testosterone therapy by pellet implant. There were no adverse clinical affects in the infant after seven months of continuous testosterone therapy to the mother by subcutaneous pellet implant. Testosterone delivered by sublingual drops, vaginal cream, and pellet implant was absorbed but not measurably excreted into breast milk. Testosterone, delivered by a 100-mg subcutaneous pellet implant, was effective in relieving symptoms of testosterone deficiency and was not measurably increased in breast milk or measurable in infant serum. Maternal testosterone therapy is safe for the breast-fed infant. Testosterone by pellet implant may be a safer and more physiologic alternative to psychotropic medications.

## PRESENTATION TOPIC

Testosterone, delivered by pellet implant, has been successfully used to treat anxiety, emotional lability, memory loss, depression, and fatigue in women.<sup>1-6</sup> These symptoms can be seen in post-partum females. "Breast feeding" has been listed as a contraindication to testosterone therapy, despite a paucity of data to support this recommendation. The Millennium Wellness Center has previously withheld testosterone therapy from nursing mothers until they discontinued breast feeding.

## SUMMARY OF PURPOSE, HYPOTHESIS, MATERIALS, METHODS, AND RESULTS

### STUDY PURPOSE AND HYPOTHESIS

The purpose of the study was to evaluate maternal absorption of testosterone and its excretion into breast milk by three methods of delivery:

- Sublingual drops, 1 mg twice daily
- Vaginal cream, 0.5 mg applied daily in the morning
- Pellet implant, 100 mg implanted in subcutaneous tissue

Based on the pharmacokinetics of drug excretion in breast milk, testosterone was not expected to be measurably excreted in breast milk (molecular size >200, nonbasic pH, significant protein binding) or absorbed into infant blood.<sup>7-11</sup> In addition, testosterone has a low/no intrinsic toxicity.

### MATERIALS AND METHODS

A 34-year-old breast-feeding mother presented with symptoms of depression, anxiety, irritability, memory loss, aches, and pains (Menopause Rating Scale [MRS] validated survey). Testosterone tested low by capillary bloodspot (ZRT Laboratory, Beaverton, Oregon) and serum. The patient was treated with testosterone, delivered by compounded preparations of sublingual drops, vaginal cream, and, lastly, subcutaneous pellet implant.

Sublingual hormones are known to peak rapidly in serum and are measurable for up to 4 hours.<sup>12</sup> Vaginal hormones have been shown to be readily absorbed and peak in serum between 4 and 6 hours.<sup>12-26</sup> Testosterone,

delivered by pellet implant, shows continuous serum levels above endogenous ranges with diurnal variation (Figure 1). Elevated serum testosterone levels, above normal "endogenous" ranges, are expected with exogenous testosterone, delivered by pellet implant. Doses of 100 mg and above have been shown to relieve symptoms without evidence of major side effects or complications.<sup>1,2,27-29</sup>

The mother was monitored for symptomatic improvement (MRS validated survey) and signs of testosterone excess (none). The male infant was monitored for clinical signs of testosterone excess (none).

### SPECIMEN COLLECTION

Baseline testosterone levels were obtained from maternal capillary blood (finger stick) and breast milk (foremilk). During sublingual and vaginal testosterone therapy, serial testosterone levels were measured at 2-hour intervals in maternal capillary blood and breast milk.

With maternal "long-acting" testosterone therapy delivered by subcutaneous pellet implant, testosterone levels were measured in maternal capillary blood and breast milk at once/twice daily intervals. Infant capillary bloodspot (heel stick) testosterone was monitored day 2, day 7, week 4, and month 5.

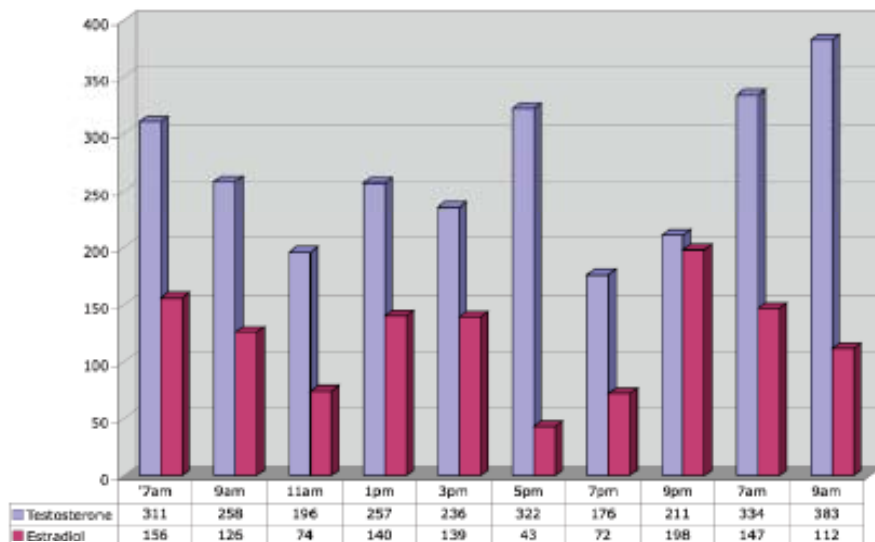
### METHODOLOGY: BREAST MILK

Samples of breast milk were analyzed by ZRT Laboratory, Beaverton, Oregon. Breast milk samples (collected into specimen tubes, labeled, and frozen) were liquid extracted with hexane. After removal of the hexane layer, an additional liquid extraction was performed by adding acetonitrile to the hexane solution to remove nonpolar lipids. After removal of the acetonitrile layer, the solvent was dried under nitrogen, and the sample reconstituted in an aqueous buffer. The same procedure was followed for assay commercially with purchased whole milk spiked with known amounts of testosterone. Reconstituted samples were assayed on a commercially available serum testosterone enzyme immunoassay (DRG International, Inc., Mountainside, New Jersey) following the addition of extracted standards and breast milk samples, and the samples were analyzed by ZRT Laboratory, Beaverton, Oregon.

### METHODOLOGY: CAPILLARY BLOODSPOT

A minimum of 6 drops of capillary blood from the fingertip (or heel of the infant) were collected onto filter paper and allowed to dry. Clinical dried blood spot samples (0.6 cm), standards, and controls were punched from dried samples and extracted twice with methanol.

**FIGURE 1. The graph shows the diurnal variation over a 26-hour period with estradiol (50 mg) and testosterone (112.5 mg) pellet implants.<sup>a</sup>**



<sup>a</sup>Measured by venous bloodspot (ZRT Laboratory, Portland, Oregon).<sup>29</sup>

Methanol was dried and samples reconstituted with assay buffer. Samples were added to a 96-well enzyme immunoassay for testosterone (DRG International, Inc.) and were analyzed by ZRT Laboratory. From this point, the standard procedure for serum testing was followed according to kit instructions and results given in ng/dL.

## SUMMARY OF STUDY RESULTS

Testosterone was measurable in maternal blood by all three methods of delivery (Tables 1 and 2). No significant increase of testosterone was seen in breast milk when testosterone was delivered by vaginal cream ( $P = .57$ ), sublingual drops ( $P = .12$ ), or subcutaneous pellet implant ( $P = .17$ ) (Figure 2). Testosterone was very low in infant blood ( $<10$  ng/dL) at baseline and during testosterone therapy by pellet implant. Serial measurements were obtained at days 2, 7, and 20, and at month 5. There were no adverse clinical affects in the male infant after 7 months of continuous testosterone therapy to the mother by subcutaneous pellet implant. Testosterone therapy by 100-mg subcutaneous pellet implant was

**TABLE 1. Absorption of Testosterone from Vaginal Cream and Sublingual Drops.<sup>a</sup>**

Maternal Capillary Testosterone (ng/dL)		
Time (H)	Vaginal Cream	Sublingual Drops
0	<10	16
2	284	186
4	104	155
6	10	58
8	<10	10
10	<10	---
12	---	<10

<sup>a</sup>Measured by capillary bloodspot at 2-hour intervals.

**TABLE 2. Absorption of Testosterone from Subcutaneous Pellet Implant.<sup>a</sup>**

Maternal Capillary Testosterone (ng/dL)	
Time (Days)	Pellet Implant
0	<10
2	283
3 (AM)	170
3 (PM)	93
7 (AM)	148
7 (PM)	123

<sup>a</sup>Measured at day 2, day 3 morning and evening, and day 7 morning and evening.

effective in relieving maternal symptoms of depression, anxiety, fatigue, decreased libido, aches, pains, and memory problems without side effects.

## CONCLUSION OF PRESENTATION

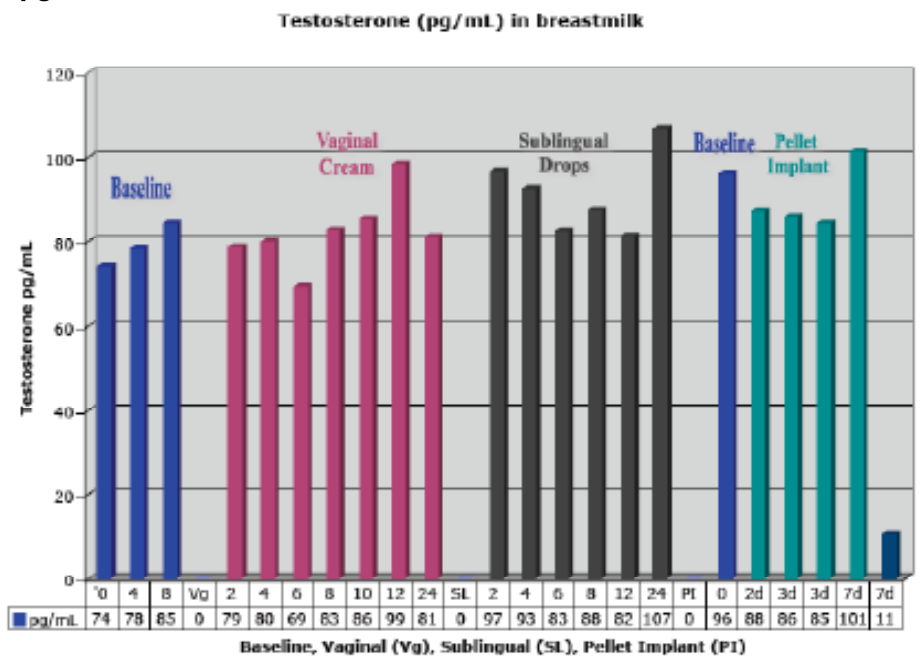
Testosterone delivered by sublingual drops, vaginal cream, and pellet implant was absorbed (measurable in maternal blood) but not measurably excreted into breast milk. Testosterone, delivered by a 100-mg subcutaneous pellet implant was effective in relieving symptoms of testosterone deficiency and was not measurably increased in breast milk or measurable in infant serum. Maternal testosterone therapy is safe for the breast-fed infant. Testosterone by pellet implant may be a safer and more physiologic alternative to psychotropic medications. Further studies should be done and unsubstantiated guidelines should be questioned and revised.

## REFERENCES

1. Burger HG, Hailes J, Menelaus M et al. The management of persistent menopausal symptoms with oestradiol-testosterone implants: Clinical, lipid and hormonal results. *Maturitas* 1984; 6(4): 351-358.
2. Brincat M, Magos A, Studd JW et al. Subcutaneous hormone implants for the control of climacteric symptoms. A prospective Study. *Lancet* 1984; 1(8367): 16-18.



**FIGURE 2. The graph shows the testosterone levels in breast milk (pg/mL).<sup>a</sup>**



<sup>a</sup>Levels taken at baseline, after maternal use of vaginal cream, after maternal use of sublingual testosterone drops, and after maternal subcutaneous testosterone pellet implant.

3. Cardozo L, Gibb DM, Tuck SM et al. The effects of subcutaneous hormone implants during climacteric. *Maturitas* 1984; 5(3): 177–184.
4. Montgomery JC, Appleby L, Brincat M et al. Effect of oestrogen and testosterone implants on psychological disorders in the climacteric. *Lancet* 1987; 1(8528): 297–299.
5. Garnett T, Studd J, Watson N et al. A cross-sectional study of the effects of long-term percutaneous hormone replacement therapy on bone density. *Obstet Gynecol* 1991; 78(6): 1002–1007.
6. Dimitrakakis C, Jones RA, Liu A et al. Breast cancer incidence in postmenopausal women using testosterone in addition to usual hormone therapy. *Menopause* 2004; 11(5): 531–535.
7. Berlin CM Jr. Sensitivity of the young infant to drug exposure through human milk. *Adv Drug Deliv Rev* 2003; 55(5): 678–693.
8. Fleishaker JC. Models and methods for predicting drug transfer into human milk. *Adv Drug Deliv Rev* 2003; 55(5): 643–652.
9. Ito S, Lee A. Drug excretion into breast milk: Overview. *Adv Drug Deliv Rev* 2003; 55(5): 617–627.
10. McManaman JL, Neville MC. Mammary physiology and milk secretion. *Adv Drug Deliv Rev* 2003; 55(5): 629–641.
11. Heinemann K, Ruebig A, Potthoff P et al. The Menopause Rating Scale (MRS) scale: A methodological review. *Health Qual Life Outcomes* 2004; 2: 45.
12. Kuhl H. Pharmacology of estrogens and progestogens: Influence of different routes of administration. *Climacteric* 2005; 8(Suppl 1): 3–63.
13. Kuhl RL, Zava DT, Wurtzbacher D. Pilot study: Absorption and efficacy of multiple hormones delivered in a single cream applied to the mucous membranes of the labia and vagina. *Gynecol Obstet Invest* 2008; 66(2): 111–118.
14. Schiff I, Tulchinsky D, Ryan KJ. Vaginal absorption of estrone and 17beta-estradiol. *Fertil Steril* 1977; 28(10): 1063–1066.
15. Schiff I, Wentworth B, Koos B et al. Effect of estradiol administration on the hypogonadal woman. *Fertil Steril* 1978; 30(3): 278–282.
16. Punnonen R, Vilksa S, Grönroos M et al. The vaginal absorption of oestrogens in postmenopausal women. *Maturitas* 1980; 2(4): 321–326.
17. Heimer GM, Englund DE. Estradiol: Absorption after long-term vaginal treatment and gastrointestinal absorption as influenced by a meal. *Acta Obstet Gynecol Scand* 1984; 63(6): 563–567.
18. Heimer GM, Englund DE. Plasma oestradiol following vaginal administration: Morning versus evening insertion and influence of food. *Maturitas* 1986; 8(3): 239–243.
19. Mattsson LA, Cullberg G. Vaginal absorption of two estradiol preparations. A comparative study in postmenopausal women. *Acta Obstet Gynecol Scand* 1983; 62(5): 393–396.

20. Cedars MI, Judd HL. Nonoral routes of estrogen administration. *Obstet Gynecol Clin North Am* 1987; 14(1): 269–298.
21. Carlström K, Pschera H, Lunell NO. Serum levels of oestrogens, progesterone, follicle-stimulating hormone and sex-hormone-binding globulin during simultaneous vaginal administration of 17beta-oestradiol and progesterone in the pre- and post-menopause. *Maturitas* 1988; 10(4): 307–316.
22. Suh-Burgmann E, Sivret J, Duska LR et al. Long-term administration of intravaginal dehydroepiandrosterone on regression of low-grade cervical dysplasia—a pilot study. *Gynecol Obstet Invest* 2003; 55(1): 25–31.
23. Keller PJ, Riedmann R, Fischer M et al. Oestrogens, gonadotropins and prolactin after intra-vaginal administration of oestradiol in post-menopausal women. *Maturitas* 1981; 3(1): 47–53.
24. Rigg LA, Hermann H, Yen SS. Absorption of estrogens from vaginal creams. *N Engl J Med* 1978; 298(4): 195–197.
25. Rosano G, Webb CM, Chierchia S et al. Natural progesterone, but not medroxyprogesterone acetate, enhances the beneficial effect of estrogen on exercise-induced myocardial ischemia in postmenopausal women. *J Am Coll Card* 2000; 36(7): 2154–2159.

26. Oriba H, Bucks D, Maibach H. Percutaneous absorption of hydrocortisone and testosterone on the vulva and forearm: Effect of the menopause and site. *Br J Derm* 1996; 134: 229–233.
27. Thom M, Collins WP, Studd JW. Hormonal profiles in postmenopausal women after therapy in subcutaneous implants. *Br J of Obstetrics and Gynaecology* 1981; 88: 426–433.
28. Gambrell RD Jr, Natrajan PK. Moderate dosage estrogen-androgen therapy improves continuation rates in postmenopausal women: Impact of the WHI reports. *Climacteric* 2006; 9(3): 224–233.
29. Glaser R, Wurtzbacher D, Dimitrakakis C. Efficacy of testosterone therapy delivered by pellet implant. *Maturitas* 2009; 63(1): S73.

Address correspondence to Rebecca L. Glaser, MD, FACS, Millennium Wellness LLC, 228 E. Spring Valley Road, Dayton, OH 45458. E-mail: rglaser@woh.rr.com



Since 1929

## Sterile Empty Vials

FDA License No. 103  
USDA License No. 629

**1 mL — 100 mL Sizes Available**

**Type I Borosilicate Glass**

**Clear and Amber Available**

**Certificate of Analysis**

**www.AllergyLabs.com**

**Phone: 1-800-654-3971**

**Fax: 1-800-811-3389**

